

## INTRACORONARY AND INTRAVENOUS ADMINISTRATION OF BASIC FIBROBLAST GROWTH FACTOR: MYOCARDIAL AND TISSUE DISTRIBUTION

ROGER J. LAHAM, MEHRDAD REZAEI, MARK POST, FRANK W. SELLKE, RENE A. BRAECKMAN, DAVID HUNG, AND  
MICHAEL SIMONS

*Angiogenesis Research Center (R.J.L., F.W.S., M.P., M.S.), and Interventional Cardiology Section (R.J.L., M.R.), Department of Medicine, Harvard Medical School, and Beth Israel Deaconess Medical, Boston, Massachusetts; and the Cardiovascular Research Division (R.A.B., D.H.), Chiron Corporation, Emeryville, California*

(Received November 25, 1998; accepted March 25, 1999)

This paper is available online at <http://www.dmd.org>

### ABSTRACT:

Therapeutic angiogenesis using various heparin-binding growth factors is a promising treatment for ischemic heart disease. Single dose intracoronary (IC) or i.v. delivery are most practical for clinical use. This study was designed to investigate the myocardial and tissue deposition of basic fibroblast growth factor (bFGF) after IC and i.v. administration in normal and chronically ischemic animals. Twenty-four Yorkshire pigs were used (12 normal and 12 ischemic animals) with IC and i.v. administration of  $^{125}\text{I}$ -bFGF (25  $\mu\text{Ci}$ ) combined with cold bFGF (30  $\mu\text{g}$ ) and heparin (3 mg). Tissue and myocardial distribution was determined at 1 and 24 h by measuring  $^{125}\text{I}$ -bFGF specific activity and by organ and light level autoradiography. The liver accounted for the majority of  $^{125}\text{I}$ -bFGF activity at 1 h ( $37.6 \pm 17.1\%$  for IC and  $42.1 \pm 17.7\%$  for i.v. delivery), with a reduction to  $2.8 \pm 1.5\%$  for IC and  $1.5 \pm 0.9\%$  for i.v. delivery by

24 h. Total cardiac specific activity at 1 h was  $0.88 \pm 0.89\%$  for IC and  $0.26 \pm 0.08\%$  for i.v. administration ( $p = .12$ ) and decreased to  $0.05 \pm 0.04\%$  ( $p = .05$ , versus 1 h) and  $0.04 \pm 0.01\%$  ( $p < .001$ , versus 1 h) at 24 h, respectively. IC but not i.v. delivery resulted in higher deposition in ischemic than normal myocardium. IC delivery resulted in enhanced bFGF deposition only in myocardial territories subtended by the infused artery. Intravenous delivery compares favorably with IC delivery with a 3- to 4-fold reduction in myocardial deposition at 1 h and with similar solid organ deposition. The less invasive nature of i.v. delivery, its potential for repeat administration, and its applicability to a larger population may offset its resultant reduced myocardial deposition. Efficacy studies are ongoing.

Occlusion of coronary arteries is often associated with development of collateral circulation in patients with atherosclerosis. Although the existence of collateral circulation in such patients is associated with improved clinical outcomes, the net effect is rarely adequate to compensate fully for the flow lost to occlusion of native epicardial coronary arteries (Charney and Cohen, 1993; Di Carli et al., 1994; Stone et al., 1995). A number of growth factors have been associated with myocardial and peripheral limb ischemia, particularly basic fibroblast growth factor (bFGF)<sup>1</sup>, acidic fibroblast growth factor, and vascular endothelial growth factor (VEGF; Slavin, 1995; Fujita et al., 1996; Li et al., 1996; Schaper, 1996; Shinohara et al., 1996; Hasdai et al., 1997; Laham and Simons, 1999), which have been shown to induce functionally significant angiogenesis in animal models of myocardial and limb ischemia (Banai et al., 1994a; Asahara et al.,

1995; Muhlhauser et al., 1995; Pearlman et al., 1995; Harada et al., 1996; Ibukiyama, 1996; Lazarous et al., 1996; Sellke et al., 1996, 1998). These promising preclinical results have rapidly led to the study of these growth factors in patients with chronic myocardial ischemia using intracoronary (IC), i.v., and local delivery (Henry et al., 1998; Laham et al., 1998, 1999).

The pharmacokinetics and tissue distribution of these growth factors administered by various techniques, however, have not been defined. Although an i.v. delivery strategy is very appealing in terms of technical safety, ease of administration, and lack of need for cardiac catheterization, it is unclear whether i.v. delivered growth factors achieve therapeutic myocardial concentrations without untoward systemic effects. In addition, IC infusions may not result in more significant myocardial deposition and retention with the added invasiveness of the delivery technique. The relevance of this tissue distribution becomes apparent when one considers the potential systemic toxicity of these agents in terms of hemodynamic effects, recirculation, and organ deposition, with the potential to induce pathologic angiogenesis and tumorigenesis (Aiello et al., 1994; Samoto et al., 1995; Favard et al., 1996; Yoshiji et al., 1996; Boulton et al., 1997; Paques et al., 1997).

Therefore, additional investigations are required to characterize the delivery of these growth factors. Such studies would help to ascertain the actual amounts of growth factors delivered to the ischemic myocardium, provide information regarding the persistence of and stability of these growth factors, and compare characteristics of different

This work was supported in part by National Institutes of Health Grants MO1-RR01032 (R.J.L.), HL 53793 and HL 44821 (M.S.), HL 42279 (F.W.S.), and a grant from Chiron Corporation.

<sup>1</sup> Abbreviations used are: bFGF, basic fibroblast growth factor; IC, intracoronary; VEGF, vascular endothelial growth factor; LCX, left circumflex coronary artery; LAD, left anterior descending coronary artery; RCA, right coronary artery;  $^{125}\text{I}$ -bFGF,  $^{125}\text{I}$ -Bolton Hunter-labeled bFGF.

Send reprint requests to: Dr. Roger J. Laham or Dr. Michael Simons, Angiogenesis Research Center, Harvard Medical School, Beth Israel Deaconess Medical Center, 330 Brookline Ave., Boston, MA 02215. E-mail: [rlaham@caregroup.harvard.edu](mailto:rlaham@caregroup.harvard.edu)

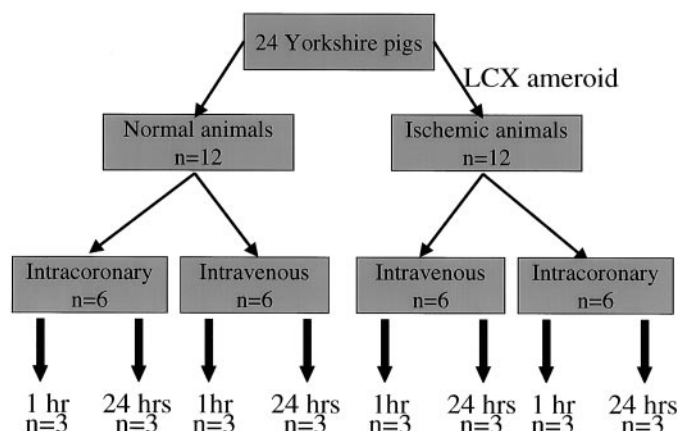


FIG. 1. Study design and performance.

Twenty-four animals were used (12 nonischemic and 12 ischemic; 3 weeks after implantation of an ameroid constrictor on the LCX).

delivery techniques. This study was designed to investigate the myocardial and tissue deposition and retention of bFGF after IC and i.v. administration in normal and chronically ischemic animals.

### Materials and Methods

Tissue distribution studies were carried out in 24 Yorkshire pigs (12 normal animals and 12 chronically ischemic animals; Fig. 1). Yorkshire pigs of either sex weighing 15 to 18 kg were anesthetized with i.m. ketamine (10 mg/kg) and halothane inhalation anesthesia. By sterile technique, a right popliteal cut down was performed and a 4 French arterial catheter was inserted for blood sampling and pressure monitoring. Left thoracotomy was performed through the 4th intercostal space during mechanical ventilation. The pericardium was opened and an ameroid constrictor of 2.5 mm internal diameter (matched to the diameter of the artery) was placed around the proximal left circumflex coronary artery (LCX; Harada et al., 1994; 1996; Lazarous et al., 1995). The pericardium was closed using 6/0 Prolene and the chest was closed. A single dose of i.v. cefazolin (70 mg/kg) was given and i.m. narcotic analgesics were administered as needed. Animals were then allowed to recover for 3 weeks (time sufficient for ameroid closure) before radiolabeled growth factor delivery. The treatment of animals was done according to National Institutes of Health guidelines and the protocol was approved by the Institutional Animal Care and Utilization Committee of the Beth Israel Deaconess Medical Center.

Ischemic animals (three weeks after ameroid placement) and normal non-instrumented animals were anesthetized with i.m. ketamine (10 mg/kg) and halothane inhalation anesthesia. By sterile technique, an i.v. line was inserted into the ear vein and a right femoral cut down was performed to introduce an 8Fr arterial sheath. Coronary angiography was then performed in multiple views using a 7 French JR4 diagnostic catheter (Cordis Laboratories, Inc., Miami, FL) to confirm LCX occlusion in ischemic animals and to assess the coronary anatomy.  $^{125}\text{I}$ -Bolton Hunter-labeled bFGF ( $^{125}\text{I}$ -bFGF; 25  $\mu\text{Ci}$ ; New England Nuclear) with a specific activity of 110  $\mu\text{Ci}/\mu\text{g}$  (4050 kBq/ $\mu\text{g}$ ) was combined with 30  $\mu\text{g}$  of cold bFGF and 3 mg of heparin (similar to the dose used in animal studies and in the recent phase I IC and i.v. human study) and was used for IC (six normal and six ischemic animals) and i.v. (six normal and six ischemic animals) delivery. For IC delivery,  $^{125}\text{I}$ -bFGF was infused in the left main coronary artery over 10 min. For i.v. delivery,  $^{125}\text{I}$ -bFGF was infused through the ear vein i.v. line over 10 min. Animals were then sacrificed 1 ( $n = 12$ ) and 24 h ( $n = 12$ ) after  $^{125}\text{I}$ -bFGF administration.

Duplicate plasma, urine (spot samples), and tissue samples from the liver, lung, kidney, and quadriceps muscle were obtained. Tissues were washed three times in saline to avoid contribution of radioactivity in blood. The heart, liver, lungs, and kidneys were weighed to determine total organ weight. Duplicate samples were also obtained from the right ventricle and from the proximal portion of the left anterior descending coronary arteries (LADs) and right coronary arteries (RCAs). A 1-cm mid left ventricular transverse slice was sectioned and cut into eight segments; each segment was divided into epicardial, mid-myocardial, and endocardial portions.  $^{125}\text{I}$ -bFGF activity was deter-

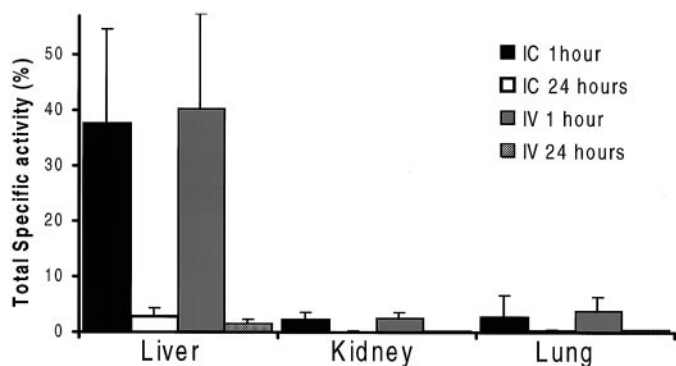


FIG. 2. Total solid organ specific activity expressed as a percentage of total  $^{125}\text{I}$ -bFGF radioactivity administered.

Total specific activity is calculated by multiplying organ specific activity (%/g) by organ weight. Results are shown for IC delivery at 1 (black column) and 24 h (white column) and for i.v. delivery at 1 (gray column) and 24 h (checkered column). Note that solid organ deposition is similar for IC and i.v. delivery at both time points, indicating significant recirculation after IC delivery. Liver deposition at 1 h accounts for a major portion of administered bFGF.

mined in a gamma counter (LKB Instruments, Inc., Gaithersburg, MD). Background was subtracted and the amount of  $^{125}\text{I}$ -bFGF deposited within a specific sample was calculated as a percentage of the total activity administered. Total solid organ deposition was calculated by multiplying the specific activity per gram of tissue by the weight of the organ. Trichloroacetic acid precipitation was performed to determine specific activity, which averaged  $86.3 \pm 24.4\%$ . A 2-mm transverse left ventricular section was obtained for organ level autoradiography and exposed in a phosphorimager for 24 h. In addition, tissue samples were obtained from the LAD and the subtended myocardium, formalin-fixed, paraffin-embedded, and 10  $\mu\text{m}$  sections were mounted on a slide, coated by a photographic emulsion for 72 h, developed, and examined using light level microscopy.

Data are expressed as mean  $\pm$  S.D. Continuous variables were compared by unpaired Student's  $t$  test, whereas categorical variables were compared by  $\chi^2$  analysis. All reported  $p$  values were two-tailed;  $p \leq .05$  was considered statistically significant.

### Results

A total of 24 animals was used for the study. Figure 1 details the study protocol. Twelve animals underwent ameroid placement on the LCX, and 3 weeks later, after confirming LCX occlusion angiographically, received  $^{125}\text{I}$ -bFGF. IC  $^{125}\text{I}$ -bFGF was administered to six normal and six ischemic animals, whereas i.v.  $^{125}\text{I}$ -bFGF was given to six normal and six ischemic animals. Tissue deposition was measured at 1 and 24 h in three animals of each group. The use of these two time points was determined by the need to study more sustained myocardial deposition and retention of  $^{125}\text{I}$ -bFGF.

**Extracardiac Deposition.** Biodistribution of the i.v. and IC radiolabeled bFGF was determined at 1 and 24 h after administration and was pooled for ischemic and nonischemic animals (Figs. 2 and 3). There were no significant differences between ischemic and nonischemic animals at each time point and the data was therefore pooled. At 1 h, the liver accounted for  $37.6 \pm 17.1\%$  of the total administered activity for IC and  $42.1 \pm 17.7\%$  for i.v. delivery ( $p = .6$ ), with a reduction to  $2.8 \pm 1.5\%$  for IC and  $1.5 \pm 0.9\%$  for i.v. delivery by 24 h ( $p = .09$ ). Total specific activity (1 h) in the kidneys was  $2.3 \pm 1.3\%$  for IC and  $2.5 \pm 1.0\%$  for i.v. delivery ( $p = .8$ ). By 24 h, total kidney specific activity decreased to  $0.1 \pm 0.05\%$  for IC and  $0.2 \pm 0.09\%$  for i.v. delivery ( $p = .1$ ). Finally, for IC and i.v. delivery, total lung specific activity was  $2.7 \pm 4.1$  and  $3.8 \pm 2.6\%$  at 1 h ( $p = .6$ ) and  $0.2 \pm 0.2$  and  $0.4 \pm 0.08\%$  at 24 h ( $p = .05$ ), respectively. Figure 3 details specific activity per milliliter for plasma, red cell sediment,

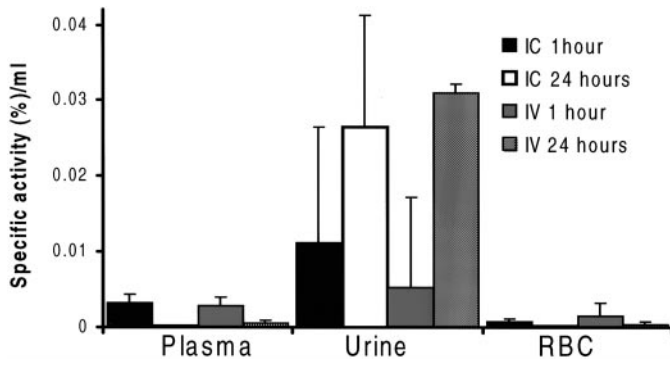


FIG. 3. <sup>125</sup>I-bFGF specific activity (% of administered activity per milliliter) of plasma, urine, and red blood cell (RBC) sediment.

Results are shown for IC delivery at 1 (black column) and 24 h (white column) and for i.v. delivery at 1 (gray column) and 24 h (checkered column). Note that plasma, urine, and RBC sediment uptake is similar for IC and i.v. delivery at both time points, indicating significant recirculation after IC delivery.

and urine. Specific activity for urine was  $0.01 \pm 0.01\%$  for IC and  $0.005 \pm 0.01\%$  for i.v. administration at 1 h and increased to  $0.02 \pm 0.01\%$  for IC and  $0.03 \pm 0.05\%$  at 24 h for i.v. delivery, however, that increase was not statistically significant.

**Cardiac Deposition.** Total cardiac specific activity is shown in Fig. 4. Total specific activity (1 h) was  $0.88 \pm 0.89\%$  for IC and  $0.26 \pm 0.08\%$  for i.v. administration ( $p = .12$ ) and decreased to  $0.05 \pm 0.04\%$  ( $p = .05$ , compared with 1 h values) and  $0.04 \pm 0.01\%$  ( $p < .001$ , compared with 1 h values) at 24 h, respectively. Left ventricular deposition is illustrated in Figs. 5, 6, and 7, and are reported for normal and ischemic animals. There were no differences between epicardial and endocardial deposition for both IC delivery; the results were pooled for further analysis. For IC delivery, LAD territory activity per gram of tissue (1 h) was  $0.01 \pm 0.007\%$  and  $0.008 \pm 0.008\%$  for normal and ischemic animals, and at 24 h dropped to  $0.0005 \pm 0.0009\%$  (20-fold reduction) in nonischemic animals and  $0.0008 \pm 0.0005\%$  (10-fold reduction) in ischemic animals. For i.v. delivery, 1-h LAD territory activity per gram of tissue was  $0.003 \pm 0.001\%$  (3-fold reduction,  $p = .2$ , compared with IC) and  $0.002 \pm 0.0009\%$  (4-fold reduction,  $p = .3$ , compared with IC) for normal and ischemic animals, and at 24 h dropped to  $0.0004 \pm 0.0001\%$  (7.5-fold reduction) in nonischemic animals and  $0.0004 \pm 0.0004\%$  (5-fold reduction) in ischemic animals, respectively. For 1-h LCX myocardial deposition, IC and i.v. deliveries resulted in a specific activity per gram of tissue of  $0.008 \pm 0.004\%$  and  $0.003 \pm 0.001\%$  (2.6-fold reduction,  $p = .09$ ) in normal animals and  $0.01 \pm 0.007\%$  and  $0.003 \pm 0.001\%$  (3.3-fold reduction,  $p = .2$ ) in ischemic animals, respectively. At 24 h, LCX deposition for IC and i.v. delivery dropped to  $0.0006 \pm 0.0008\%$  and  $0.0005 \pm 0.0002\%$  in normal animals and  $0.0006 \pm 0.0006\%$  and  $0.0004 \pm 0.0004\%$  in ischemic animals, respectively. For all groups, RCA myocardial distribution was similar to LAD and LCX distribution for i.v. administration. However, for IC delivery, RCA myocardial deposition was significantly lower than LAD or LCX myocardial deposition, because the radiolabel was infused in the left main coronary artery. Finally, for IC delivery, LCX/LAD territory activity was 79 and 154% for nonischemic and ischemic animals at 1 h and 116% and 75% for nonischemic and ischemic animals at 24 h, respectively. Intravenous administration resulted in an LCX/LAD activity of 97 and 100% for nonischemic and ischemic animals at 1 h and 123% and 98% for nonischemic and ischemic animals at 24 h, respectively.

Myocardial autoradiography (Figs. 6 and 7) confirmed myocardial deposition for both IC and i.v. delivery with three times enhanced

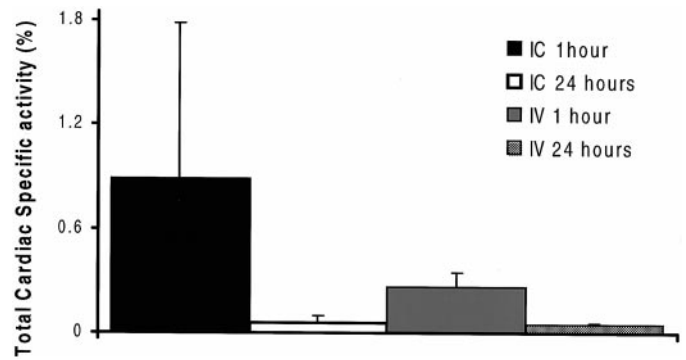


FIG. 4. Total cardiac specific activity (percentage of total activity administered) for both IC and i.v. delivery at 1 and 24 h.

Although activity is similar for both IC and i.v. delivery at 24 h, IC administration results in approximately a 3-fold increase in 1-h <sup>125</sup>I-bFGF myocardial deposition.

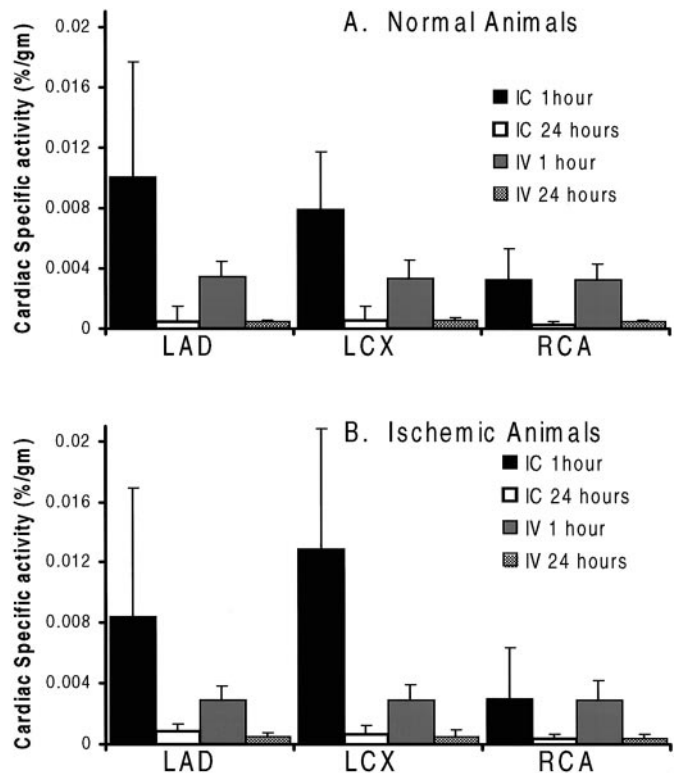


FIG. 5. Regional cardiac specific activity (percentage of total activity administered per gram of tissue) for the LAD, LCX, and RCA myocardial territory in normal (nonischemic) animals (A) and ischemic animals (B).

Note that i.v. delivery results in equal <sup>125</sup>I-bFGF deposition in all myocardial territories at 1 h, whereas IC delivery results in higher deposition at 1 h in the infused arteries, with specific activity similar to i.v. delivery in the noninfused territories (RCA). Twenty-four-hour deposition is similar in all territories for both delivery strategies. Furthermore, there is increased deposition in the ischemic LCX territory at 1 h.

deposition for IC delivery compared with i.v. delivery at 1 h with near equalization of tissue deposition at 24 h (measured using densitometric analysis). In addition, IC delivery resulted in increased deposition in LAD and LCX deposition compared with RCA (noninfused territory) deposition, whereas i.v. delivery resulted in a more uniform distribution in the three myocardial territories by qualitative analysis. Light level autoradiography (Fig. 8) after 72-h exposure showed LAD endothelial deposition for IC delivery after 1 h. Evaluation of other arteries for IC delivery at 24 h and for all coronary arteries at all time

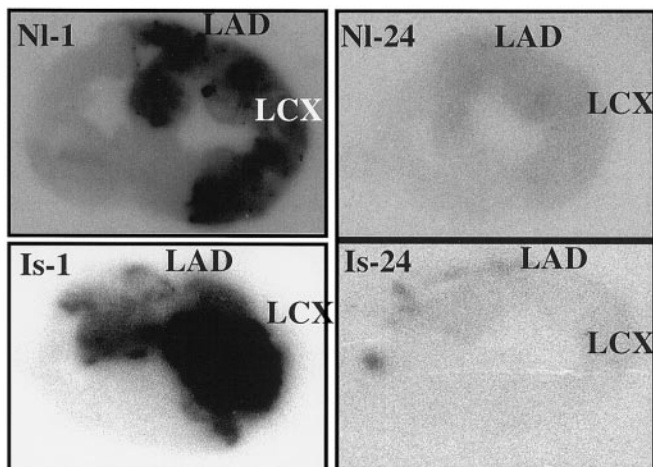


FIG. 6. Organ level myocardial autoradiography for IC delivery for normal (nonischemic animals, top) and ischemic animals (bottom) at 1 (left) and 24 h (right).

Figures represent a mid-transverse left ventricular slice with right ventricle to the left and left ventricle to the left. Note the low activity in noninfused territory (inferior wall supplied by the RCA) at 1 h. Ischemic myocardial  $^{125}\text{I}$ -bFGF deposition is enhanced at 1 h for IC delivery.

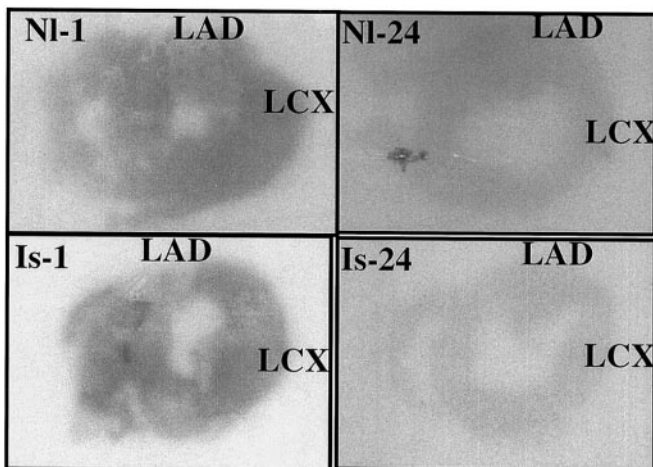


FIG. 7. Organ level myocardial autoradiography for i.v. delivery for normal (nonischemic animals, top) and ischemic animals (bottom) at 1 (left) and 24 h (right).

Figures represent a mid-transverse left ventricular slice with right ventricle to the left and left ventricle to the left. Note the equal activity in all territories at 1 h.

points failed to show  $^{125}\text{I}$ -bFGF deposition even after 96 h of exposure.

### Discussion

The availability of various heparin-binding growth factors, particularly bFGF and VEGF, the demonstration of their *in vitro* and *in vivo*

angiogenic potential, and the identification of their role in physiologic and pathologic angiogenesis (Ladoux and Frelin, 1993; Aiello et al., 1994; Banai et al., 1994b; Gabra et al., 1994; Fujita et al., 1996; Li et al., 1996; Boulton et al., 1997; Hasdai et al., 1997) have propelled their study in human ischemic heart disease and peripheral vascular disease (Isner et al., 1996; Henry et al., 1998; Laham et al., 1998; 1999; Laham and Simons, 1999). Given the typically long time course of new collateral vessel development, most preclinical attempts to stimulate myocardial angiogenesis have used methods of prolonging growth factor delivery including gene therapy, continuous infusions, repeated injections, or sustained release polymers (Banai et al., 1994; Harada et al., 1994, 1996; Asahara et al., 1995; Pearlman et al., 1995; Yang et al., 1996; Laham and Simons, 1999). However, some of these options such as repeated intracardiac injections or infusions are either unfeasible or impractical in patients with ischemic heart disease, making single dose administration, if effective, a potentially superior strategy in these patients. This led to the investigation of these agents delivered via the IC or i.v. route (Battler et al., 1993; Lopez et al., 1998), methods more applicable to patients. However, IC and i.v. administrations are associated with significant systemic recirculation. This becomes relevant when one considers the potential systemic toxicity of these agents in terms of hemodynamic effects, recirculation, and organ deposition, with the potential to induce pathologic angiogenesis and tumorigenesis (Aiello et al., 1994; Samoto et al., 1995; Favard et al., 1996; Yoshiji et al., 1996; Boulton et al., 1997; Paques et al., 1997). In fact, the IC delivery of VEGF resulted in hypotension, which was the dose-limiting toxicity. Finally, i.v. delivery with its ease of use, noninvasive characteristics, and potential for repeated administration make this strategy, if safe and effective, an ideal delivery technique for these mitogenic growth factors.

Biodistribution studies are warranted to ascertain the actual amounts of growth factors delivered to the ischemic myocardium, provide information regarding the persistence and stability of these growth factors, and compare characteristics of IC and i.v. delivery. The current study was designed to investigate the myocardial and tissue deposition and retention of bFGF after IC and i.v. administration in normal and chronically ischemic animals.

Both IC and i.v. delivery strategies resulted in the majority of radiolabel being deposited in the liver. Surprisingly, liver deposition was similar for both techniques, indicating significant recirculation for IC delivery. In addition, these results confirm the previous observation that the liver is the major organ of elimination with circulating bFGF binding to  $\alpha$ -2-macroglobulin, which in turn is internalized by receptors on Kupffer cells (Whalen et al., 1989; LaMarre et al., 1991). This result was duplicated for renal and lung deposition. It is important to point out that bFGF was infused in the ear vein (above the diaphragm). However, this simulates i.v. delivery in patients where the port of entry would probably be an upper extremity vein bypassing

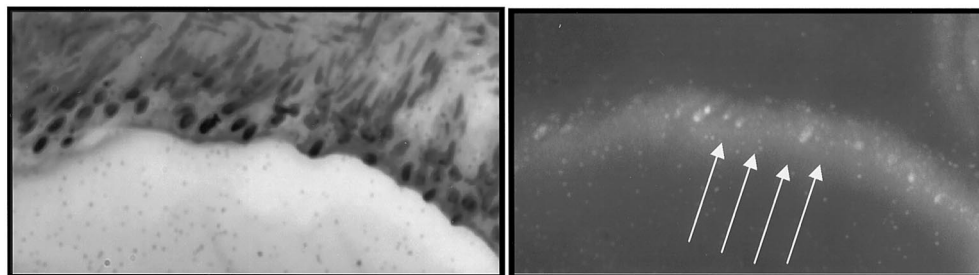


FIG. 8. Light microscopic level autoradiography.

Histologic section (40X) of LAD (left) and darkfield microscopy of the same field (right) show LAD endothelial deposition for IC delivery.

the liver first pass mechanism. Therefore, IC delivery does not result in less systemic deposition, probably due to high recirculation.

One-hour total and regional myocardial deposition was 3- to 4-fold higher for IC compared with i.v. delivery, and deposition dropped by 5- to 20-fold at 24 h. IC delivery resulted in higher deposition in ischemic myocardium, possibly related to the increased expression of fibroblast growth factor receptors associated with myocardial ischemia. This was not seen in i.v. delivery, possibly related to the initial concentrations delivered to the ischemic myocardium. Thus IC delivery, by providing higher initial concentrations in the coronary circulation, may result in higher deposition in ischemic areas. These comparisons, although consistent, did not reach statistical significance due to the small number of animals studied.

Of note, IC delivery resulted in enhanced bFGF deposition compared with i.v. delivery only in myocardial territories subtended by the infused artery. Therefore, for IC delivery to provide an advantage over i.v. delivery, infusion should be carried out in all coronary arteries and bypass grafts if present. Whether infusing a larger dose of bFGF would result in similar myocardial deposition to IC delivery (a more invasive approach) was not investigated. For IC delivery, bFGF was identified on the endothelial cells of the infused arteries, where it might exert its effect. In addition, this study raises an important question of whether more local or sustained delivery is necessary for bFGF effect, particularly with the relatively low cardiac deposition for both delivery modalities. The study was not designed to test efficacy, however, an endpoint to be determined in human clinical studies currently underway.

Although it has been demonstrated that perivascular delivery results in significantly lower systemic levels and solid organ deposition than i.v. delivery (Edelman et al., 1993), this is the first study that systematically examined the myocardial deposition of i.v. and IC bFGF delivery in both normal and ischemic animals, the latter duplicating methods currently studied in human angiogenesis trials. This study underscores above all the potential need for "true" local delivery if IC and i.v. administration results in clinically significant systemic toxicities. Our results are comparable to the results obtained by Lazarous et al. (1997) in a smaller number of animals where i.v. delivery resulted in a 10-fold reduction in 15-min myocardial deposition.

This study has several limitations including the small sample size (to limit radioactive disposal and personnel exposure). In addition, the time point studied may miss earlier events, particularly that circulating bFGF half-life may be much shorter than 1 h (Edelman et al., 1993; Lazarous et al., 1997). Whether bFGF deposition in the first few minutes after administration are crucial for its sustained effects is unknown.

## CONCLUSION

This study details the myocardial and tissue deposition and retention of bFGF after IC and i.v. administration in normal and chronically ischemic animals. Intravenous delivery compares favorably with IC delivery with a 3- to 4-fold reduction in myocardial deposition and similar solid organ deposition. The less invasive nature of the former delivery technique, the potential for repeat administration, and its applicability to a larger population may offset its resultant reduced myocardial deposition. It is crucial, however, to determine whether i.v. delivery results in therapeutic myocardial levels, a question that can only be answered by studying its ability to induce functional angiogenesis in animals and human myocardial ischemia.

**Acknowledgments.** We thank Denise Saleem, Melissa Miller, Jian Li, and David Cohen.

## References

- Aiello LP, Avery RL, Arrigg PG, Keyt BA, Jampel HD, Shah ST, Pasquale LR, Thieme H, Iwamoto MA and Park JE (1994) Vascular endothelial growth factor in ocular fluid of patients with diabetic retinopathy and other retinal disorders. *N Engl J Med* **331**:1480-1487.
- Asahara T, Bauters C, Zheng LP, Takeshita S, Bunting S, Ferrara N, Symes JF and Isner JM (1995) Synergistic effect of vascular endothelial growth factor and basic fibroblast growth factor on angiogenesis in vivo. *Circulation* **92**(Suppl II):365-371.
- Banai S, Jaklitsch MT, Shou M, Lazarous DF, Scheinowitz M, Biro S, Epstein SE and Unger EF (1994a) Angiogenic-induced enhancement of collateral blood flow to ischemic myocardium by vascular endothelial growth factor in dogs. *Circulation* **89**:2183-2189.
- Banai S, Shweiki D, Pinson A, Chandra M, Lazarovici G and Keshet E (1994b) Upregulation of vascular endothelial growth factor expression induced by myocardial ischaemia: Implications for coronary angiogenesis. *Cardiovasc Res* **28**:1176-1179.
- Battler A, Scheinowitz M, Bor A, Hasdai D, Vered Z, Di Segni E, Varda-Bloom N, Nass D, Engelberg S and Eldar M (1993) Intracoronary injection of basic fibroblast growth factor enhances angiogenesis in infarcted swine myocardium. *J Am Coll Cardiol* **22**:2001-2006.
- Boulton M, Gregor Z, McLeod D, Charteris D, Jarvis-Evans J, Moriarty P, Khaliq A, Foreman D, Allamby D and Bardsley B (1997) Intravitreal growth factors in proliferative diabetic retinopathy: Correlation with neovascular activity and glycaemic management. *Br J Ophthalmol* **81**:228-233.
- Charney R and Cohen M (1993) The role of the coronary collateral circulation in limiting myocardial ischemia and infarct size. *Am Heart J* **126**:937-945.
- Di Carli M, Sherman T, Khanna S, Davidson M, Rokhsar S, Hawkins R, Phelps M, Schelbert H and Maddahi J (1994) Myocardial viability in asynergic regions subtended by occluded coronary arteries: Relation to the status of collateral flow in patients with chronic coronary artery disease. *J Am Coll Cardiol* **23**:860-868.
- Edelman ER, Nugent MA and Karnovsky MJ (1993) Perivascular and intravenous administration of basic fibroblast growth factor: Vascular and solid organ deposition. *Proc Natl Acad Sci USA* **90**:1513-1517.
- Favard C, Ortega N, Bayard F and Plouet J (1996) Vascular endothelial growth factor and retinal neovascularisation: A new therapeutic approach for diabetic retinopathy. *Diabetes Metab* **22**:268-273.
- Fujita M, Ikemoto M, Kishishita M, Otani H, Nohara R, Tanaka T, Tamaki S, Yamazato A and Sasayama S (1996) Elevated basic fibroblast growth factor in pericardial fluid of patients with unstable angina. *Circulation* **94**:610-613.
- Gabra N, Khayat A, Calabresi P and Khayat A (1994) Detection of elevated basic fibroblast growth factor during early hours of in vitro angiogenesis using a fast ELISA immunoassay. *Biochem Biophys Res Commun* **205**:1423-1430.
- Harada K, Friedman M, Lopez JJ, Wang SY, Li J, Prasad PV, Pearlman JD, Edelman ER, Sellke FW and Simons M (1996) Vascular endothelial growth factor administration in chronic myocardial ischemia. *Am J Physiol* **270**:H1791-H1802.
- Harada K, Grossman W, Friedman M, Edelman ER, Prasad PV, Keighley CS, Manning WJ, Sellke FW and Simons M (1994) Basic fibroblast growth factor improves myocardial function in chronically ischemic porcine hearts. *J Clin Invest* **94**:623-630.
- Hasdai D, Barak V, Leibovitz E, Herz I, Sclarovsky S, Eldar M and Scheinowitz M (1997) Serum basic fibroblast growth factor levels in patients with ischemic heart disease. *Int J Cardiol* **59**:133-138.
- Henry T, Rocha-Singh K, Isner J, Kereiakes D, Giordano F, Simons M, Losordo D, Hendel R, Bonow R, Rothman J, Borbas E and McCluskey E (1998) Results of intracoronary recombinant human vascular endothelial growth factor (rhVEGF) administration trial. *J Am Coll Cardiol* **31**:65A.
- Ibukiyama C (1996) Angiogenesis. Angiogenic therapy using fibroblast growth factors and vascular endothelial growth factors for ischemic vascular lesions. *Jpn Heart J* **37**:285-300.
- Isner JM, Pieczek A, Schainfeld R, Blair R, Haley L, Asahara T, Rosenfield K, Razvi S, Walsh K and Symes JF (1996) Clinical evidence of angiogenesis after arterial gene transfer of phVEGF165 in patient with ischaemic limb. *Lancet* **348**:370-374.
- Ladoux A and Frelin C (1993) Hypoxia is a strong inducer of vascular endothelial growth factor mRNA expression in the heart. *Biochem Biophys Res Commun* **195**:1005-1010.
- Laham R, Leimbach M, Chronos N, Vansant J, Pearlman J, Pettigrew R, Guler H, Whitehouse M, Hung D, Baim D, King S and Simons M (1999) Intracoronary administration of recombinant fibroblast growth factor-2 (rFGF-2) in patients with severe coronary artery disease: Results of phase I. *J Am Coll Cardiol* **33**:383A.
- Laham R, Sellke F, Edelman J and Simons M (1998) Local perivascular basic fibroblast growth factor (bFGF) treatment in patients with ischemic heart disease. *J Am Coll Cardiol* **31**:394A.
- Laham R and Simons M (1999) Therapeutic angiogenesis in myocardial ischemia, in *Angiogenesis and Cardiovascular Disease* (Simons W ed) pp 289-320, Oxford University Press, New York.
- LaMarre J, Wollenberg GK, Gonias SL and Hayes MA (1991) Cytokine binding and clearance properties of proteinase-activated alpha 2-macroglobulins. *Lab Invest* **65**:3-14.
- Lazarous DF, Scheinowitz M, Shou M, Hodge E, Rajanayagam S, Hunsberger S, Robison WG Jr, Stiber JA, Correa R, Epstein SE and Unger E (1995) Effects of chronic systemic administration of basic fibroblast growth factor on collateral development in the canine heart. *Circulation* **91**:145-153.
- Lazarous DF, Shou M, Scheinowitz M, Hodge E, Thirumurti V, Kitsiou AN, Stiber JA, Lobo AD, Hunsberger S, Guetta E, Epstein SE and Unger EF (1996) Comparative effects of basic fibroblast growth factor and vascular endothelial growth factor on coronary collateral development and the arterial response to injury. *Circulation* **94**:1074-1082.
- Lazarous DF, Shou M, Stiber JA, Dadhania DM, Thirumurti V, Hodge E and Unger EF (1997) Pharmacodynamics of basic fibroblast growth factor: Route of administration determines myocardial and systemic distribution. *Cardiovasc Res* **36**:78-85.
- Li J, Brown LF, Hibberd MG, Grossman JD, Morgan JP and Simons M (1996) VEGF, flk-1, and flt-1 expression in a rat myocardial infarction model of angiogenesis. *Am J Physiol* **270**:H1803-H1811.
- Muhlhauser J, Pili R, Merrill MJ, Maeda H, Passaniti A, Crystal RG and Capogrossi MC (1995) In vivo angiogenesis induced by recombinant adenovirus vectors coding either for secreted or nonsecreted forms of acidic fibroblast growth factor. *Hum Gene Ther* **6**:1457-1465.
- Paques M, Massin P and Gaudric A (1997) Growth factors and diabetic retinopathy. *Diabetes Metab* **23**:125-130.

- Pearlman JD, Hibberd MG, Chuang ML, Harada K, Lopez JJ, Gladstone SR, Friedman M, Sellke FW and Simons M (1995) Magnetic resonance mapping demonstrates benefits of VEGF-induced myocardial angiogenesis. *Nat Med* **1**:1085–1089.
- Samoto K, Ikezaki K, Ono M, Shono T, Kohno K, Kuwano M and Fukui M (1995) Expression of vascular endothelial growth factor and its possible relation with neovascularization in human brain tumors. *Cancer Res* **55**:1189–1193.
- Schaper W (1996) Collateral vessel growth in the human heart. Role of fibroblast growth factor-2. *Circulation* **94**:600–601.
- Sellke FW, Li J, Stamler A, Lopez JJ, Thomas KA and Simons M (1996) Angiogenesis induced by acidic fibroblast growth factor as an alternative method of revascularization for chronic myocardial ischemia. *Surgery* **120**:182–188.
- Sellke FW, Tofukuji M, Laham RJ, Li J, Hariawala MD, Bunting S and Simons M (1998) Comparison of VEGF delivery techniques on collateral-dependent microvascular reactivity. *Microvasc Res* **55**:175–178.
- Shinohara K, Shinohara T, Mochizuki N, Mochizuki Y, Sawa H, Kohya T, Fujita M, Fujioka Y, Kitabatake A and Nagashima K (1996) Expression of vascular endothelial growth factor in human myocardial infarction. *Heart Vessels* **11**:113–122.
- Slavin J (1995) Fibroblast growth factors: At the heart of angiogenesis. *Cell Biol Int* **19**:431–444.
- Stone DA, Corretti MC, Hawke MW, Herzog W, Rodriguez S and Plotnick GD (1995) The influence of angiographically demonstrated coronary collaterals on the results of stress echocardiography. *Clin Cardiol* **18**:205–208.
- Whalen GF, Shing Y and Folkman J (1989) The fate of intravenously administered bFGF and the effect of heparin. *Growth Factors* **1**:157–164.
- Yang HT, Deschenes MR, Ogilvie RW and Terjung RL (1996) Basic fibroblast growth factor increases collateral blood flow in rats with femoral arterial ligation. *Circ Res* **79**:62–69.
- Yoshiji H, Gomez DE, Shibuya M and Thorgeirsson UP (1996) Expression of vascular endothelial growth factor, its receptor, and other angiogenic factors in human breast cancer. *Cancer Res* **56**:2013–2016.